



PATIENT

Niko Lorenzo

SPECIES

Feline

BREED

Ragdoll

SEX

Male Intact

AGE

1 years

WEIGHT

6lbs

INTERPRETED BY

Maggie Machen Lamy,
DVM, DACVIM
(Cardiology)

IMAGING PERFORMED BY

G. Ferrer, DVM

HOSPITAL NAME

Pulse: Pet Ultrasound
Services

REFERRING VET

Dr. Ferrer

INVOICE

46560

DATE

1/23/26

PRESENTING CLINICAL SIGNS

- Presented to rDVM with open mouth breathing, abdominal breathing and decreased appetite.
- Pleural effusion on radiographs
- Thoracocentesis was done: yellow slightly viscous fluid, modified transudate / high protein transudate.
- Feline Corona virus PCR negative
- Pt is on Clavamox and started yesterday on Furosemide 1-2mg/kg q 6-8 hrs and Plavix

Abnormal PE/Chem/CBC/UA Results: ECG showed an LAD. No pathologic arrhythmias are observed.

ECHOCARDIOGRAM FINDINGS

2D, m-mode, color flow and doppler imaging is available. The left ventricular wall is borderline increased in dimension. There is a mildly hyperechoic endocardium. The papillary muscles are hyperechoic. Both atrial appear mildly dilated. The right ventricle appears normal. The mitral valve is normal in structure and mobility. Trace MR. Blood flow through both the LVOT and RVOT is normal in velocity. Scant pericardial effusion. Pockets of pericardial effusion seen. No obvious cardiac tumors.

CARDIAC CHART

FELINE CARDIAC PARAMETERS	BODY WEIGHT (kg)	HR (BPM)	IVSd (cm) <small>(Moise, Pipers)</small>	LVIDd (cm) <small>(Moise, Pipers)</small>	LVWd (cm) <small>(Moise, Pipers)</small>	FS (%)	EF (%)
NORMAL PARAMETER	-----	150-240	0.35-0.55	<2 (mean 1.5)	3.5-0.55	35-67	80-100
PATIENT	2.7	156	0.57	1.4	0.56	44	80
FELINE CARDIAC PARAMETERS	LA/AO <small>(Boon)</small>	LA/AO HEART BASE (Swe) <small>(Abbott)</small>	LA 2D short axis Base view (cm) <small>(Abbott)</small>	LVOT VEL <small>(m/s)</small>	RVOT VEL <small>(m/s)</small>	E max <small>(m/s)</small>	
NORMAL	<1.5	<1.3	<1.2	<1.6	<1.3	<0.9	
PATIENT	NM	1.5	1.4	1.2	0.9	NM	

**Note: All measurements based upon multi-modal images and methods. An average value is reported.
Adapted from June Boon, Veterinary Echocardiography, 1998
Abbott J & MacLean H JVIM 2006;20: 111-119, Moise et al. Am J Vet Res 47:1476, 1986. Pipers et al. Am J Vet Res 40:882, 1979.*

INTERPRETATION OF THE FINDINGS & FURTHER RECOMMENDATIONS

The only abnormality identified is mild biatrial enlargement and borderline LV hypertrophy. The latter is suspected to be secondary to volume depletion with active effusion; however, early HCM cannot be ruled out. Monitoring is advised. Both atrial appear mildly dilated, which may reflect some degree of underlying structural disease.

Mild biatrial enlargement would suggest that CHF is an unlikely cause of pleural effusion (FIP, infectious/inflammatory, etc). That being said, any atrial enlargement does raise concern. Full work up is advised in search of other possible issues such as FIP, pulmonary pathology, etc. Consider fluid cytology, focused thoracic ultrasound, CT scan, systemic evaluation. If CHF is suspected, certainly a diuretic trial is recommended to assess for improvement.



PATIENT

Niko Lorenzo

SPECIES

Feline

BREED

Ragdoll

SEX

Male Intact

AGE

1 years

WEIGHT

6lbs

INTERPRETED BY

Maggie Machen Lamy,
DVM, DACVIM
(Cardiology)

IMAGING PERFORMED BY

G. Ferrer, DVM

HOSPITAL NAME

Pulse: Pet Ultrasound
Services

REFERRING VET

Dr. Ferrer

INVOICE

46560

DATE

1/23/26

Prognosis is guarded prior to determining the definitive diagnosis and assessing for progression.

Monitor for any clinical evidence of cardiac compromise, including respiratory changes and/or signs of a blood clot event (paralysis, neurologic changes, etc).

Anesthesia, fluid or steroid therapy is not advised at this time.

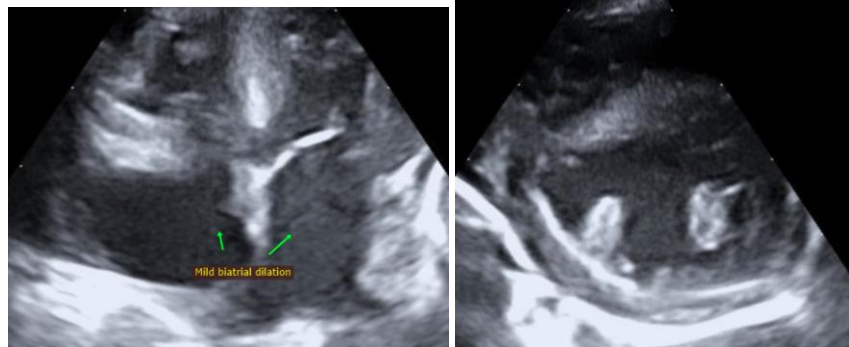
PLAN

Consider further work up, fluid cytology, response to diuretic therapy, systemic work up, etc. If CHF is most likely, institute Lasix 1-2mg PO q12h and assess response.

Monitor renal values and BP in 1-2 weeks, then every 3-4 months life. If patient improves on diuretic therapy, addition of Plavix is also suggested.

Recommend recheck echocardiogram in 6 months to screen for progression, sooner if any recurrent issues arise in the interim.

IMAGES



The information and recommendations provided are based on the images presented by the referring veterinarian. No evaluation can be communicated regarding pathology that was not visible in the image/video clips provided.

Thank you for this referral. This report was generated using transcription software, and minor dictation errors may be present. If the clinical or image interpretation does not parallel your findings or if I can be of any further assistance, please contact me.

Maggie Machen Lamy, DVM
Diplomate of the American College of Veterinary Internal Medicine (Cardiology)
info@sonopath.com